LONGITUDINAL MODIFICATIONS OF THE CONNECTOME OF A MOUSE MODEL OF ALZHEIMER'S DISEASE

Laetitia Degiorgis[1], Meltem Karatas[1], Marion Sourty[1], Emilie Faivre[4], Vincent Noblet[1], Julien Lamy[1], Thomas Bienert[2], Marco Reisert[2], Chantal Mathis[3], Anne-Laurence Boutiller[3], David Blum[4], Frédéric Blanc[1,5], Jean-Paul Armspach[1] and Laura Adela Harsan[1,2,6]

[1]ICube, Université de Strasbourg-CNRS, Strasbourg, France, [2]Department of Radiology, Medical Physics, University Medical Center Freiburg, Freiburg, Germany, [3]Laboratoire de Neurosciences Cognitives et Adaptatives, Université de Strasbourg-CNRS, Strasbourg, France, [4]Centres Mémoire de Ressources et de Recherche, CHU de Strasbourg, Services Neurologiques et Gériatriques, [5] Département de Biophysique et Médecine Nucléaire, Hôpitaux Universitaires de Strasbourg, CHU de Hautepierre, France

Objective

To study the evolution of the brain connectome in a mouse model of tauopathy → Reveal potential biomarkers of the evolution of Alzheimer's disease

Longitudinal, non-invasive, and *in-vivo* study

5 months → 9 months → 13 months

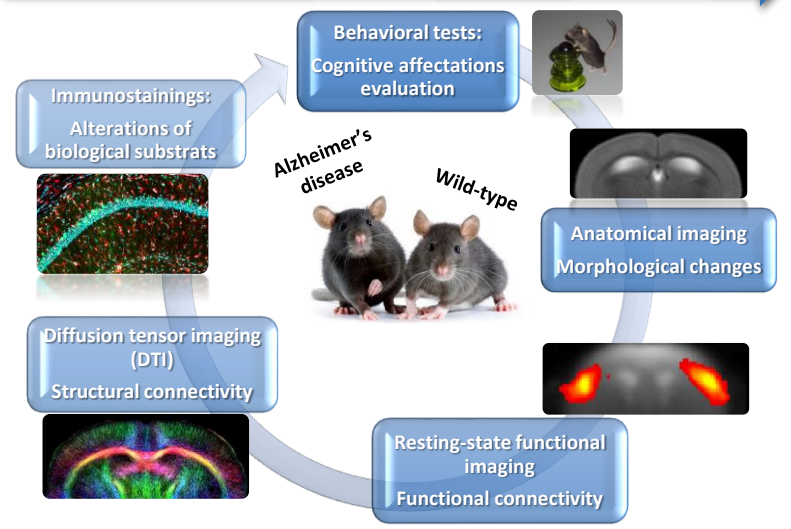

Methods

The Thy-Tau22 mouse : a tauopathy mouse model



Transgenic mouse model: overexpression of the mutated tau protein

Hyper-phosphorylated tau accumulation

3 months | 7 months | 12 months

Neurofibrillary tangles-like formation

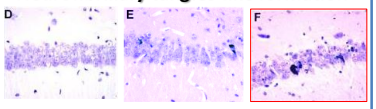

3 months | 7 months | 12 months

Age-dependant accumulation of pathological tau

Schindowski et al., 2006

Animals : 2 groups : Thy-Tau22 (Tau) (n=16) and Wild-Type (WT) (n=13)

Memory test : the object recognition test

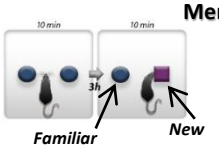

Phase 1 Habituation: mice explore the objects in the open-field for 10 minutes

Phase 2 Retention: mice have to detect the new object and recognise the familiar one

Image acquisition and processing

7T MRI

→ **Acquisition**: Imaging was performed under anesthesia (medetomidine) by s.c. infusion of 0.3mg MD/kg-Body-Weight/hour.

- **MRI Sequences**: Anatomical MRI: T2 Turbo-RARE, Diffusion tensor imagi DTI-EPI and Resting-state functional MRI: GE-EPI.

→ **Processing**:

- **Morphological analysis**: Voxel-based morphometry (VBM)
- **Functional connectivity**: BOLD signal extraction (0.01-0.1Hz) followed by seed-based correlation's analysis of regions of interest (ROIs).
- **Structural connectivity**: Voxel-based quantification (VBQ) of the fraction of anisotropy.

Immunostaining

Coronal brain sections (35 µm) were obtained from 5, 9 and 12 months Thy-Tau22 and WT mice. Stainings were realized using antibody directed against phosphorylated Tau at Ser202/Thr205 sites (AT8 antibody) to look at hyperphosphorylated tau, and sections were counterstained with DAPI to reveal nuclei .

Results

1. Memory disturbance in 9 months Thy-Tau22 mice

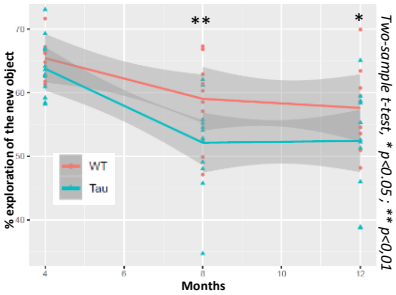

Thy-Tau22 mice display memory deficits starting 9 months in the object-recognition test

5 | 9 | 13

Prodromal

Intermediate

Late

2. Atrophy and Hypertrophy in Thy-Tau22 mice starting at 9 months

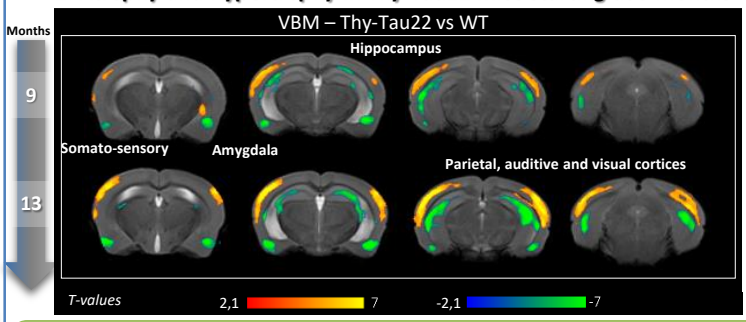

- No morphological changes in prodromal Thy-Tau22 (5 months)
- **From 9 months** and increasing at **13 months**, transgenic mice display **hippocampal and amygdala atrophy**, in addition with **cortical hypertrophy**

3. Early modifications of the septo-hippocampal pathway

Connecting the **hippocampus and the septum** (LS), the **fornix** (fx) is early affected in 5 months **Thy-Tau22** mice, reflecting **early microstructural alterations**, increasing over time

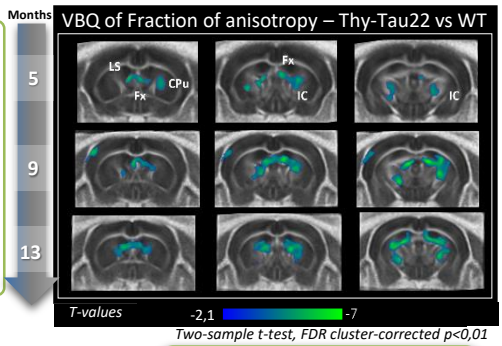

Two-sample t-test, FDR cluster-corrected p<0,01

Longitudinal functional analysis showed **modifications of the septal functional connectivity** over time in **Thy-Tau22**, but not in WT mice

Immunostaining in **Thy-Tau22** mice showed **early deposition of pathological Tau** (AT8 – green) in the **hippocampus, the fornix** and the septum

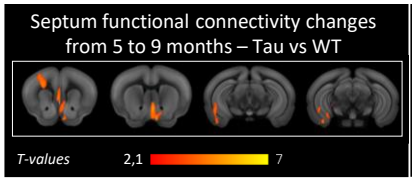

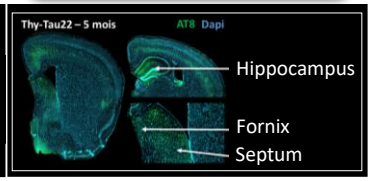

Two-way ANOVA, FDR cluster-corrected p<0,05

Conclusion

- **Early microstructural alterations** of the septo-hippocampal pathway, without showing any memory deficit at this stage.
- **Increase** of those affectations **at 9 months** in addition with **functional modifications** of the septal network, and **hippocampal atrophy**, that may lead to the begining of **memory impairment**.
- **Early tau deposition** in related areas of the septo-hippocampal pathway that may underlie **structural and functional modifications**.
- **Atrophy of the amydgala** -one of the main node of the limbic system with the hippocampus and the septum- that may strongly contribute to this system alterations

Université de Strasbourg | FHU Neurogenycs | iCUBE | cnrs