A novel cohort of Al Kaissi syndrome: functional studies of bi-allelic variations of the *CDK10* gene, about one case

Manon CHRETIEN[1,16], Adella KARAM[1], Amélie PITON[2], Theresa BRUNET[3], Perrine CHARLES[4], Claude DARCHA[5], Evren GÜMÜS[6], Bertrand ISIDOR[7], Kimia KAHRIZI[8], Vincent MICHAUD[9], Renske OEGEMA[10], Juliette PIARD[11], Davut PEHLIVAN[12], Laure RAYMOND[13], Marcia RODRIGUES[14], Pierre COLAS[15], Hélène DOLLFUS[1,16], Elise SCHAEFER[1,16], Jean MULLER[1,2]

[1]Laboratoire de Génétique Médicale, INSERM, UMR_S 1112, CRBS, Université de Strasbourg, France ; [2]Laboratoires de Diagnostic Génétique, Nouvel Hôpital Civil, Strasbourg, France ; [3]Institute of Human Genetics, Technical University of Munich, Germany ; [4]Service de Génétique Clinique et Médicale, Hôpital La Pitié Salpêtrière, Paris, France ; [5]Service d'Anatomopathologie, CHU Estaing, Clermont-Ferrand, France ; [6]Medical Genetics Department, Mugla Sitki Kocman University, Turkey ; [7]Service de Génétique Médicale, CHU de Nantes, France ; [8]Medical Genetics Research Center University of Social Welfare and Rehabilitation Sciences, Evin Theran, Iran ; [9]Service de Génétique Médicale, CHU de Bordeaux, France ; [10]Clinical Genetics, Universitair Medisch Centrum (University Medical Center), Utrecht, Pays-Bas ; [11]Service de Génétique Médicale, CHU Saint-Jacques, Besançon, France ; [12]Pediatrics and Neurology, Baylor College of Medicine, Texas Children's Hospital, Houston, Texas, US ; [13]Laboratoire Eurofins Biomnis, Lyon, France ; [14]Serviço de Genética Médica, Hospital de Santa Maria, CHU Lisboa Norte, Lisboa, Portugal ; [15]Station Biologique UMR8227 CNRS, Sorbonne Université, Roscoff, France ; [16]Service de Génétique Médicale, IGMA, CRBS, Strasbourg, France.

manon.chretien@chru-strasbourg.fr

Introduction

CDK10 encodes a Cyclin Q-Dependent Kinase (CDK) expressed in almost all tissues and having a role in proliferation, transcription and splicing. The silencing of CDK10/Cyclin Q couple promote the assembly and elongation of the primary cilia[1]. CDK10 has been implicated in the Al Kaissi syndrome (#MIM617694, autosomal recessive), a recently described ciliopathy, often associating major intrauterine growth retardation and postnatal growth delay, hypotonia, moderate to severe intellectual disability, thin corpus callosum, dysmorphic facial features and spinal segmentation defects. Since 2017, only 14 individuals from 9 unrelated families have been reported with mainly loss of function variations[2]. We have recently established a novel cohort of 15 individuals with a very suggestive phenotype of Al Kaissi syndrome that carry bi-allelic variations in *CDK10*. Among the 16 identified variations (of all types), 7 remain so far of uncertain significance (like missenses, inframe indel…) and therefore require validation studies. **Here we described one case of the cohort and a part of its functional characterization involving in particular the study of cell morphology (percentage of ciliated cells, length of the primary cilium) as well as the exploration of the Sonic HedgeHog (SHH) pathway.**

Affected individuals and Methods

- **Affected individuals:**
  Recruitment thanks to ANDDI-Rares, ERN-ITHACA, GeneMatcher and Achropuce network.
- **Molecular diagnosis**:
  « Intellectual disability » / « Callosome » multigene panels testing, whole exome sequencing (WES), CGH-array.
- ***CDK10* gene expression:**
  Skin fibroblast cultures under basal (+FCS, Fetal Calf Serum) and ciliary (-FCS, 48H of deprivation) conditions.
- **Ciliary cellular phenotype and study of the SHH pathway:**
  Cilium staining by immunofluorescence, skin fibroblast cell culture under ciliary condition (-FCS, 48H). SHH pathway analysis using Smoothened AGonist (SAG) for induction +/- FCS (48H).

Results and discussion (example for patient A.II.2)

- **Patient A.II.2**

Born from a Caucasian non-consanguineous union (Fig 1.A) with IUGR, severe post-natal growth retardation (-5 SD), developmental delay, thin corpus callosum with enlarged ventricles, ASD (Atrial Septal Defect), dysmorphic features (Fig 1.B) and vertebral bodies segmentation defect (C2-C3 fusion) (Fig 1.C).

- **Genetic Analysis**

Variant 1: Missense affecting a highly conserved amino acid : c.461T>C; p.Leu154Pro (Fig.2A ; B) **(variant of unknown significance, VUS, class 3).**

Variant 2: In frame deletion : c.628_630del; p.Leu211del (Fig.2C) **(VUS).**

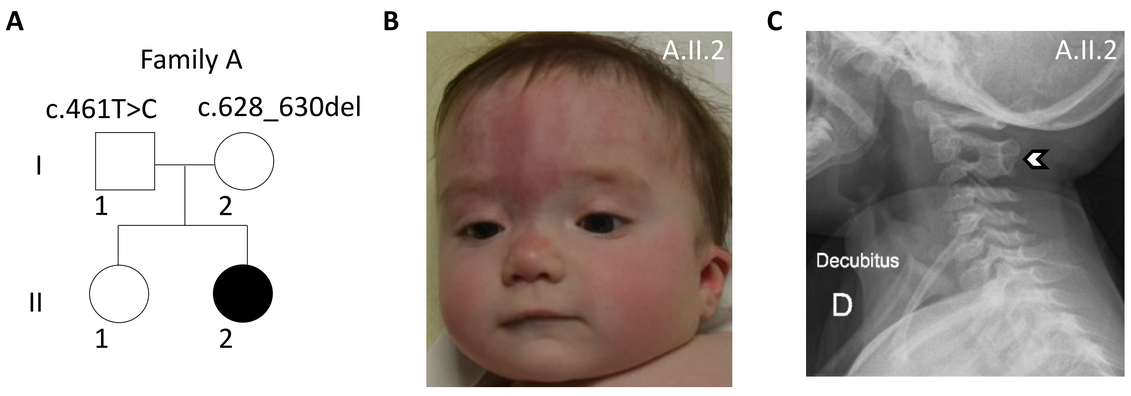

Figure 1: A. Pedigree. **B.** Front face photograph of patient A.II.2. **C.** X-rays of the skeleton (White head arrows showing fusions of the cervical vertebrae).

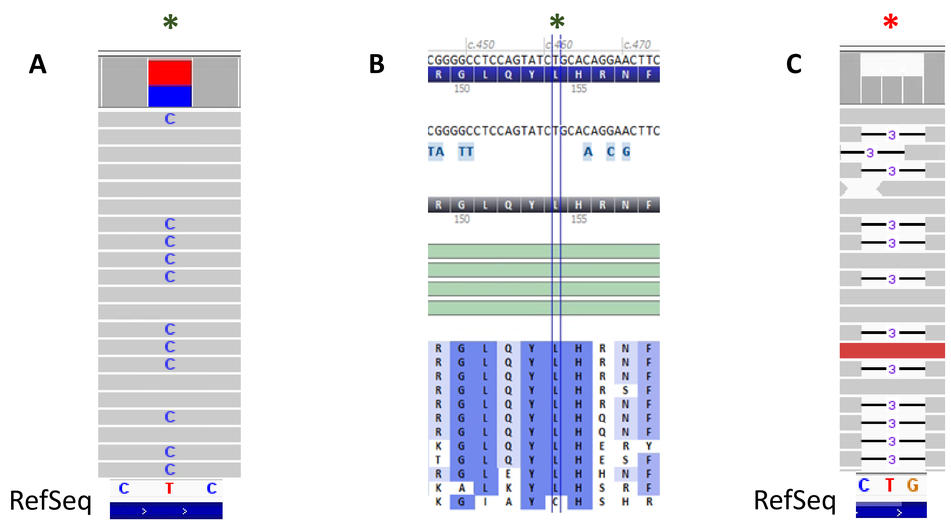

Figure 2: A. Visualization of the heterozygous missense using IGV (Integrative Genomics Viewer) **B.** Bioinformatic prediction for the conserved amino acid p.Leu154Pro **C.** Visualization of the heterozygous in frame deletion using IGV.

Results and discussion (example for patient A.II.2)

- **Quantitative study of *CDK10* gene expression and qualitative impact on the *CDK10* transcript**

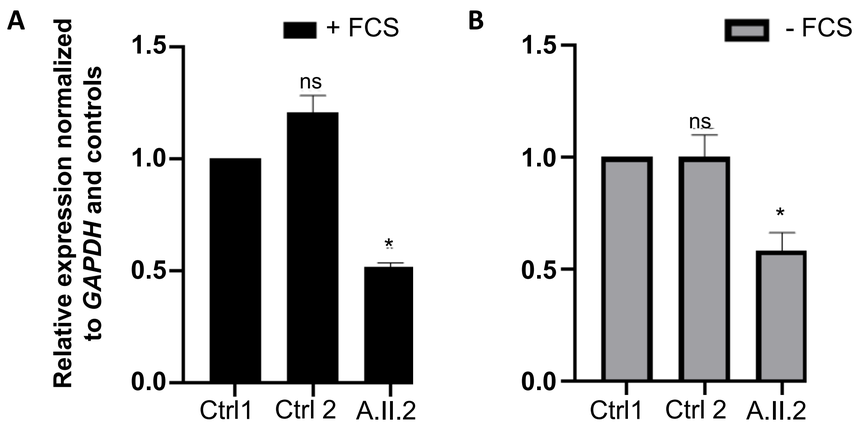

Figure 3: *CDK10* expression (qRT-PCR) for patient A.II.2 in **A.** normal condition (+FCS) **B.** ciliogenesis condition (-FCS) (ANOVA test: * $p \leq 0.05$)
ns (+FCS): p = 0,1669
ns (-FCS): p > 0,9999

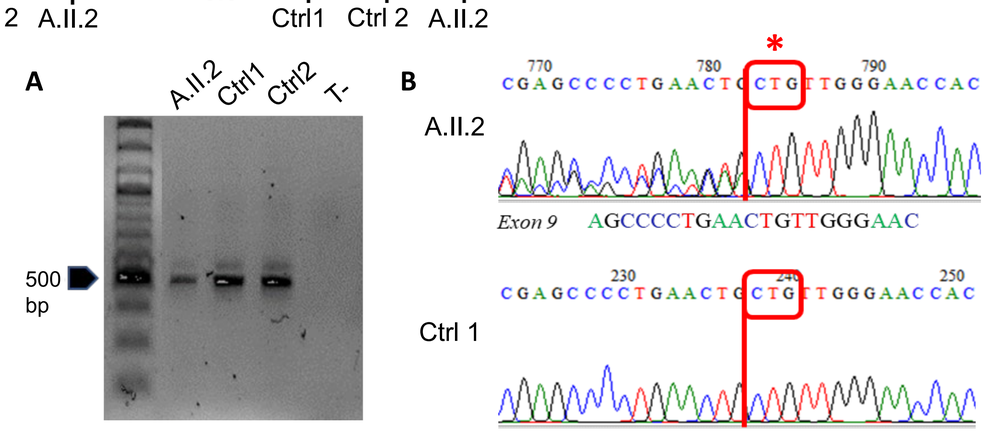

Figure 4: PCR from cDNA of patient A.II.2 with **A.** Gel deposition **B.** Sanger sequencing (antisense strand)

- *CDK10* expression reduced by half for patient A.II.2 with no difference after activation of ciliogenesis (-FCS) (Fig.3A and B). The 50% decrease in *CDK10* expression appears to be related to a contribution from both alleles (c.461T>C and c.628_630del) with 2 overlapping sequences from the CTG* deletion (Fig.4A and B).

- **Ciliary cellular phenotype and SHH pathway**

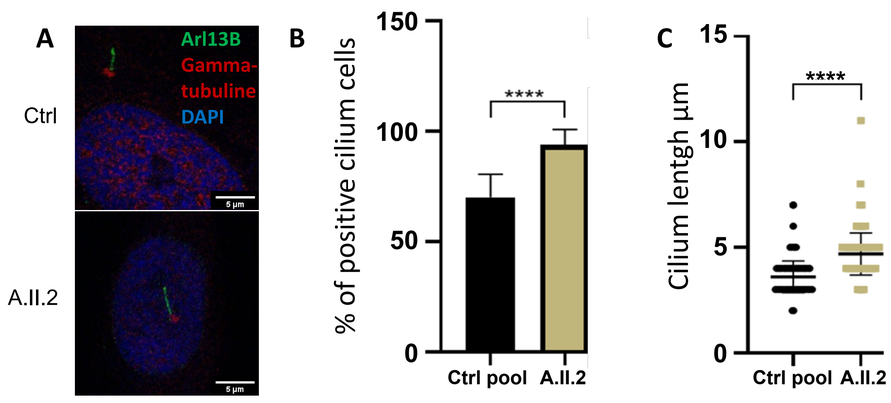

Figure 5: A. Cilia immunostaining of the A.II.2 patient's skin fibroblast. **B.** Quantification of ciliogenesis (ANOVA test: **** $p \leq 0.0001$) and **C.** measurement of cilia length (Kruskal-Wallis test: **** $p \leq 0.0001$)

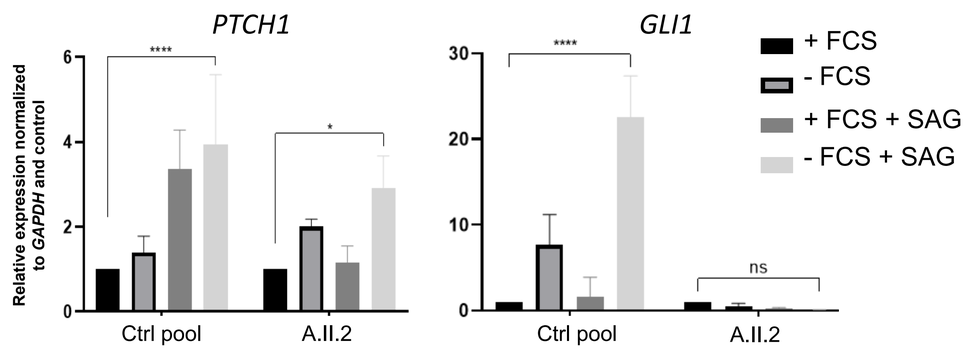

Figure 6: *PTCH1* and *GLI1* expression (qRT-PCR in 4 conditions, +/- FCS and SAG) (ANOVA test : * $p \leq 0.05$; **** $p \leq 0.0001$; ns : p = 0.9989)

- The patient A.II.2 has more ciliated cells (n=900) (Fig.5B) and longer primary cilium (n=400) (Fig.5C), compared to the controls (n=5). SHH pathway activation is less important in the patient's fibroblasts (Fig.6).

Conclusion

This is the largest cohort of Al Kaissi patients. To date, functional analyses have validated 6 out of 7 VUS. This work extends the clinical and mutational spectrum of Al Kaissi syndrome and provides a better understanding of its natural history and its membership in the heterogeneous group of ciliopathies.

[1]Guen et al., 2016, [2]Windpassinger et al., 2017